



E-ISSN: 2616-3470
P-ISSN: 2616-3462
© Surgery Science
www.surgeryscience.com
2018; 2(1): 05-09
Received: 02-11-2017
Accepted: 03-12-2017

Dr. Pablo Naranjo Garcia
Elite Laser Clinic. Madrid, Spain

Dr. Jorge Alberto Elias
Gynesthetic Health and Aesthetic
Center. Buenos Aires, Argentina

Dr. Jorge Gaviria Parada
Fotomedicine Institute. Teknon
Medical Center. Barcelona, Spain

Dr. Daniel Zarza Lucianez
Laser Department. Vithas Nisa
Pardo de Aravaca Hospital

Dr. Hernan Raul Pinto
I2e3 Biomedical Research
Institute. Barcelona, Spain

Anatomical outcomes of therapy with LEDs in combination with intra vaginal CO2 vs Er: YAG fractional lasers to treat vaginal atrophy

Dr. Pablo Naranjo Garcia, Dr. Jorge Alberto Elias, Dr. Jorge Gaviria Parada, Dr. Daniel Zarza Lucianez and Dr. Hernan Raul Pinto

Abstract

Background: Vaginal atrophy affects nearly of 50% of postmenopausal women. The study aimed to evaluate the use of intra vaginal light-emitting diodes after laser procedure for vaginal atrophy treatment, to minimize laser side effects.

Methods: The study included 2 groups of treatment with 30 women in each. Group 1: one session of laser alone; Group 2: one session of laser, and immediately after, one session with Floreo® LED. Patients were followed-up for one month. Variables: distance urethra-vagina, thickness AA and AP, and vascularization.

Results: At post-treatment, group 1 showed more signs of edema and inflammation. Differences were statistically significant for thickness AA ($P=0.0014$), thickness AP ($P=0.0003$), and vascularization ($p<0.0001$). One month post-treatment, both groups had similar anatomical values with no significant differences.

Conclusion: Intra vaginal light-emitting diodes immediately after laser procedure, significantly minimized post laser treatment normal or expected transitory side effects, without diminishing its efficacy.

Keywords: Genitourinary syndrome of menopause, vaginal atrophy, vaginal regeneration, low-power light therapy, light-emitting diodes phototherapy

Introduction

Vaginal atrophy (VA) or genitourinary syndrome of menopause (GSM), accordingly to the Vaginal Atrophy Terminology Consensus Conference Panel ^[1], is a common and underreported condition associated with decreased estrogenization of the vaginal tissue. It affects nearly 50% of postmenopausal women. However, other causes of hypoestrogenic state that may lead it such as lactation, various breast cancer treatments, and use of certain medications ^[2]. Common genital symptoms include dryness, burning, and irritation, as well as other related with sexual relationships or urinary symptoms due to the lack of lubrication, discomfort or pain, and impaired function, dysuria, and recurrent urinary tract infections.

With declining levels of estrogen, the vagina experiment several changes: epithelium thins, blood flow and lubrication decrease, the elasticity is reduced and connective tissue increases ^[2]. The syndrome is characterized by an involution of the genitourinary mucosa and adjacent vaginal tissues and by histologically in a reduction of the quantity of elastic fibers of collagen and in vascularization of the genitourinary tissues. As epithelial cells exfoliate and die; they release glycogen, which is hydrolyzed to glucose. Glucose, in turn, is broken down into lactic acid by the action of lactobacillus, thus pH in the vagina rises, resulting in a loss of lactobacilli and an overgrowth of other bacteria, including group B streptococcus, staphylococci, coliforms, and diphtheroids that may cause symptomatic vaginal infections and inflammation ^[3].

Choice of therapy will depend on the severity of symptoms, the effectiveness, and safety of therapy, taking into account patient preference. Several therapeutic options are available that can be included in two groups: hormonal and nonhormonal products ^[4].

LED is a nonhormonal option for the treatment of VA that has recently gained interest. Regenerative medicine offers new ways of being able to replace, restore, or regenerate damages or diseased tissue and organs and further, to reestablish normal function in the human body, controlling the inflammatory response, accelerating tissue repair, and reducing pain. The molecular effects of LLLT are not well studied but the clinical effects of increased proliferation and viability of tissue have been demonstrated in dentistry and dermatology, with reduction of

Correspondence
Dr. Hernan Raul Pinto
I2e3 Biomedical Research
Institute. Barcelona, Spain

patient reported pain, anti-inflammatory effects, wound healing and remodeling of collagen [5].

New microablativ fractional CO₂ lasers (CO₂-laser) [6] and Erbium-doped yttrium aluminium garnet lasers (Erbium: YAG Glaser) appear feasible options in VVA treatment, improving vaginal health by activating growth factors, resulting in an increase in vascularity, collagen, extracellular matrix production, and thickness of vaginal epithelium [7]. Histology specific to vaginal tissue after CO₂ laser treatment shows a general structural improvement in the connective tissue with new active fibroblasts, collagen and ground substance and the presence of typical blood capillaries representing healthy vascularization [8]. However, laser procedures are associated with a mild post-operative side effects such as discomfort, erythema and edema, leading to a temporary increase of tissue thickness and vascularization [9].

New intra vaginal light-emitting diodes (LEDs) at appropriate wavelengths and parameters, is an effective therapeutic modality, due to promote healing of skin wounds with similar biological effects to LLLT [10]. With LEDs phototherapy through cellular photo activation, it can be achieved useful bio reactions without heat or damage [11]. Some studies have reported on the use of LED phototherapy for the rejuvenation of chronologically and photo damaged skin. Based on the published data, pain, including postoperative pain, postoperative edema and many types of inflammation can be significantly reduced [12].

The study aim was to evaluate the effectiveness of LEDs therapy to control the secondary normal or expected transitory side effects of the Laser and on the improve treatment outcomes. The hypothesis was that intravaginal LEDs therapy, applied immediately after the laser procedure, helps to reduce the side effects of the laser, such as edema and inflammation, and promotes tissue regeneration, regardless of the type of laser used.

Materials and methods

Study design

This was a prospective, multi-center and double arm study was conducted at Elite Laser Clinic (Madrid, Spain), Gynesthetic Health and Aesthetic Center (Buenos Aires, Argentina), Fotomedicine Institute. Teknon Medical Center (Barcelona, Spain), and Laser Department. Vithas Nisa Pardo de Aravaca Hospital (Madrid, Spain). Study participants included women (n=60) with symptoms of vaginal atrophy (stinging, burning, dyspareunia), with or without menopause, able to understand the study related information and agreed to participate in the study. Key exclusion criteria included previous hormonal or other treatments for VA.

The study was conducted in accordance with the principles set forth in the current revised version of the Declaration of Helsinki, with the Good Clinical Practice (GCP) and in compliance with all applicable laws and regulatory requirements relevant to the use of devices in Spain and Argentina. Individual subject records were maintained in the investigator's Sources Documents. The CRF did not include any personal data.

Study protocol

Consecutive patients were invited to participate in the study. After agreeing and meeting inclusion criteria were distributed in two treatment groups.

Treatment group 1: patients underwent a treatment with intravaginal laser, fractional Femi Lift/Pixel CO₂-laser (Alma Lasers, Israel) or an Erbium: YAG SP Dynamis (Fotona, Slovenia), and were followed up for a month.

Treatment group 2: patients underwent a treatment with intra vaginal laser, fractional Femi Lift/Pixel CO₂-laser (Alma Lasers, Israel) or an Erbium: YAG SP Dynamis (Fotona, Slovenia). Immediately after laser procedure, all patients both received a session with intra vaginal LEDs model Floreo® (Qlarite SAS. Paris, France). Patients were followed up for a month.

Treatment procedures

CO₂-laser procedure was following new Femi lift protocol for VA: low energy (10 W), 90mJ/pixel and 4 passes in all length of the vaginal canal. This device has been specifically designed to offer minimally invasive CO₂ laser-based treatment that induces collagen deposition via concentrated thermal heating of the inner vaginal tissue layer [13].

Erbium: YAG procedure was based on Renovalase protocol: according to the technique SMOOTH® pulse for non-ablative vaginal collagen neogenesis and remodeling; 1.75 J/cm² and hand piece R11GCc of 7 mm, made 4 passes in all length of the vaginal canal and 2Hz of frequency [14].

Intra vaginal LEDs protocol was 3 min with blue LED (415 nm), 3 min with red LED (660 nm) and 3 min with infrared LED (850 nm). (Figure 1)



Fig 1: Floreo® LED device (Qlarité SAS. Paris, France) **A:** Floreo® red LED device. **B:** Floreo® LEDs platform with 3 devices: blue, red and infrared. **C:** Floreo® LED protector.

Data assessments

Variables analyzed: age, distance urethra to vagina (mm), tissue vascularization (micro vessels per mm²), epithelium wall thickness (mm), thickness AA (point located 3 cm proximal to external urethral meatus on anterior vaginal wall, corresponds to urethra vesical crease) [15] and thickness AP (point located in the midline of the posterior vaginal wall 3cm proximal to the hymen) [16]. Data were collected at baseline, immediately after treatment and at one month after.

The distance urethra to vagina and thickness AA and AP were measured with a Tran's vaginal echo grapy at pre-treatment, post-treatment and at one month after treatment. Vascularization was assessed through an intra vaginal Angio-Doppler at pre-treatment, post-treatment and at one month after treatment.

Basal assessments: Trans vaginal echography was performed to all patients to measure the distance urethra-vagina and thickness AA vs AP, and an intra vaginal Angio-Doppler to evaluate the tissue vascularization. Groups were compared to evaluate statistical differences.

Post-treatment assessments (immediately after): Tran's vaginal echo grapy to evaluate the level of edema by measuring the distance urethra-vagina and thickness AA and AP, and an

Angio-Doppler to assess the tissue inflammation by the assessment of the vascularization increase. All measures were compared with basal data and between treatment groups to evaluate statistical differences.

One month post-treatment assessments: Tran’s vaginal echography to evaluate the tissue regeneration by measuring the distance urethra-vagina, the thickness AA and AP, and an Angio-Doppler was performed to assess the tissue revascularization. All echography measures were analyzed by an external Doctor and compared with basal data and between treatment groups to evaluate statistical differences. Adverse events were assessed at all visits.

In each group data were managed as a unique sample when at baseline there were no statistical differences between CO2 laser and Erbium: YAG (group 1) or CO2 laser +LEDs and Erbium: YAG + LEDs (group 2). When at baseline variables had significant differences, data were managed as absolute data as percentage of increase or decrease.

Statistical analysis included appropriate measures for statistical significance (Student’s paired two-sample t test) using the standard cutoff for significance of $P < 0.05$ via Microsoft Excel. Unless otherwise stated, quantitative variables are described as the mean \pm standard deviation (SD), whereas categorical variables are described as percentage.

Results

The study included 60 women. There were no significant age differences between groups; mean age was 55.96 ± 7.54 years (range 42-74). In the two groups all patients completed the study.

Anatomic measures

Baseline assessments: There were not significant differences in distance of urethra-vagina ($p = 0.8603$) and vascularization ($p = 0.6674$), there were significant differences among subgroups in thickness AA and AP due to the menstrual cycle or to vaginal atrophy in post-menopausal women.

Post treatment assessments

Distance urethra vagina: In group 1 mean value was 65.6 ± 12.50 mm and significantly different from the baseline 47.03 ± 11.01 ($p < 0.0001$). In group 2 mean value was 59.30 ± 13.00 and significantly different from the baseline 47.53 ± 10.90 ($P = 0.0003$). Differences among groups 1 and 2 were no significant ($P = 0.0606$). (Figure 2)

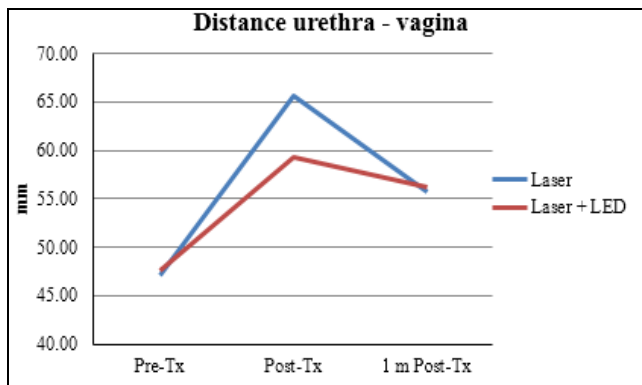


Fig 2: Measures of distance in millimeters urethra-vagina at pre-treatment, post-treatment and at one month after. Tx: treatment

Vascularization: In group 1 mean value was 5.67 ± 1.12 micro vessels per mm^2 and significantly different from the baseline

2.00 ± 0.95 micro vessels per mm^2 ($p < 0.0001$). In group 2 mean value was 3.07 ± 0.78 and significantly different from the baseline 1.90 ± 0.84 micro vessels per mm^2 ($p < 0.0001$). Differences among groups 1 and 2 were statistically significant ($p < 0.0001$). (Figure 3)

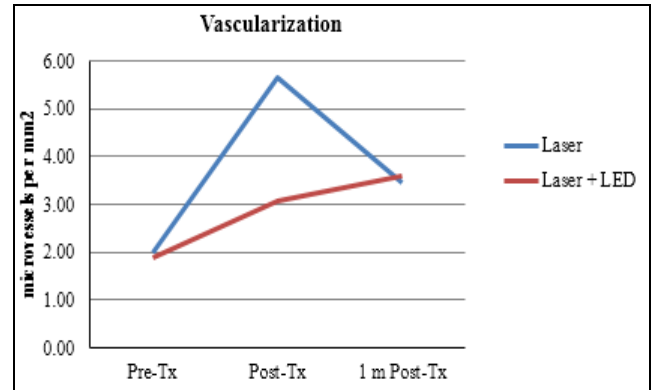


Fig 3: Micro vessels per mm^2 at pre-treatment, post-treatment and at one month after. Tx: treatment

Thickness AA: In group 1 mean value of percentage of increase of thickness AA from baseline was $73.27 \pm 46.17\%$ and in group 2 was $39.83 \pm 28.92\%$. Differences among groups 1 and 2 were statistically significant ($P = 0.0014$). (Figure 4)

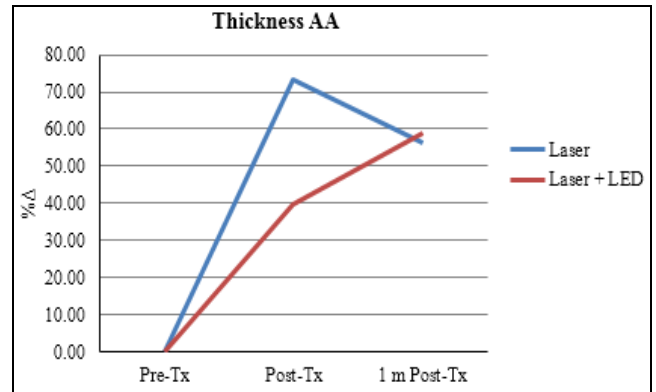


Fig 4: Percentage of increase (%Δ) of thickness AA at pretreatment, post treatment and at one month after. Tx: treatment

Thickness AP: In group 1 mean value of percentage of increase of thickness AP from baseline was $71.55 \pm 48.11\%$ and in group 2 was $33.15 \pm 25.97\%$. Differences among groups 1 and 2 were statistically significant ($P = 0.0003$). (Figure 5)

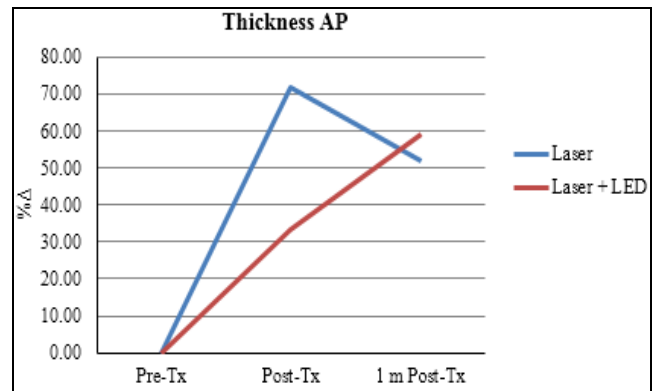


Fig 5: Percentage of increase (%Δ) of thickness AA at pretreatment, post treatment and at one month after. Tx: treatment

At one month post treatment

Distance urethra vagina: In group 1 mean value was 55.67 ± 12.18 and significantly different from the baseline 47.03 ± 11.01 mm ($P=0.0055$). In group 2 mean value was 56.23 ± 11.69 mm and significantly different from the baseline 47.53 ± 10.90 mm ($P=0.0042$). Differences among groups 1 and 2 were no significant ($P=0.8565$). (Figure 2)

Vascularization: In group 1 mean value was 3.47 ± 1.07 micro vessels per mm^2 and significantly different from the baseline 2.00 ± 0.95 micro vessels per mm^2 ($p < 0.0001$). In group 2 mean value was 3.60 ± 0.56 and significantly different from the baseline 1.90 ± 0.84 micro vessels per mm^2 ($p < 0.0001$). Differences among groups 1 and 2 were no statistically significant ($P=0.5578$). (Figure 3)

Thickness AA: In group 1 mean value of percentage of increase of thickness AA from baseline was $56.25 \pm 47.12\%$ and in group 2 was $58.97 \pm 43.01\%$. Differences of increment from post treatment to one month after in treatment group 1 and 2 were no statistically significant ($P=0.1630$) and ($P = 0.0477$) respectively. Differences among groups 1 and 2 were no statistically significant ($P = 0.8162$). (Figure 4)

Thickness AP: In group 1 mean value of percentage of increase of thickness AP from baseline was $51.5 \pm 45.30\%$ and in group 2 was $59.14 \pm 55.26\%$. Differences of increment from post treatment to one month after in treatment group 1 and 2 were ($P=0.1097$) and ($P=0.0232$) respectively. Differences among groups 1 and 2 were no statistically significant ($P=0.5837$). (Figure 5)

Safety findings

Treatments did not require analgesia/anesthesia. There were no treatment complications and adverse effects associated with LEDs treatment, only post-treatment normal or expected transitory side effects associated with fractional laser treatment. Patients did not refer pain with LED treatment.

Discussion

Laser Therapy has long been considered as a precise and predictable treatment modality to treat vaginal atrophy due its ability of tissue regeneration and collagen remodeling through heat-induced collagen contraction. However, side effects are associated with laser after the procedure such as erythema and edema. The addition of LEDs phototherapy to minimize these side effects and promote regeneration is a new option proposed in this study. Our results showed that intra vaginal LEDs may be of help to improve the management of side effects of VA fractional laser treatment and potentially increase patient's satisfaction.

The rationale behind LEDs is based on by its reported efficacy at a cellular and subcellular level, particularly for the 660 nm and 850nm wavelengths. LED phototherapy may improve blood flow and neovascularization, induce a large variety of cytokines, chemokines and macromolecules, promote collagenesis/collagenase imbalance, and reduce pain, including postoperative pain and significantly reducing postoperative edema, as well as many types of inflammation [11].

The anatomical measures were chosen because they are objective and easy to perform. However, it would be interesting carry out more studies including qualitative assessments, for example, MBS (Most Bothering Symptom), VHIS (Vaginal Health Index Scale), FSFI (Female Sexual Function Index) and ICQ-SF (Incontinence Questionnaire Short Form) to assess patient perception.

The Angio-Doppler was used to assess the thickness of the epithelium to see the change of vascularization after procedure. On treated structures only the resonance is better than the ultrasound as a diagnostic test. However, we decided to use the Angio-Doppler to avoid risks of ionizing radiation to the participants.

In our study the inclusion of one single session of phototherapy with intra vaginal light-emitting diodes immediately after laser procedure, helped significantly to minimize the post treatment side effects, without diminishing its efficacy. (Figures 6 and 7).

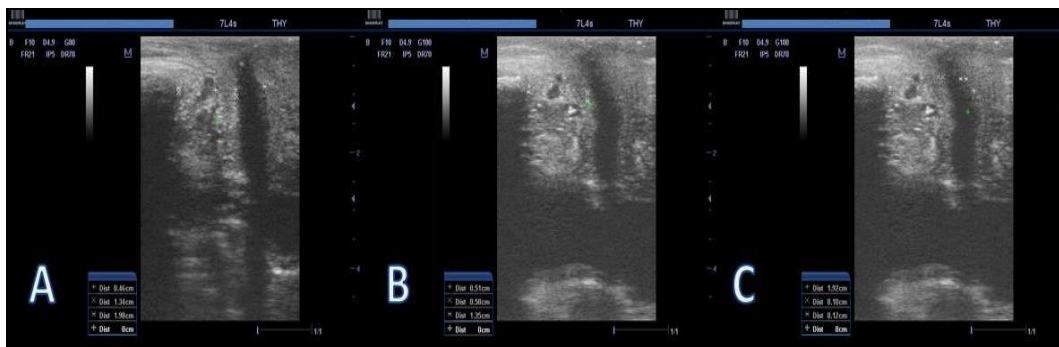

Fig 6: Transvaginal Echography at pre-treatment (A), post-treatment (B), and one month post treatment (C).

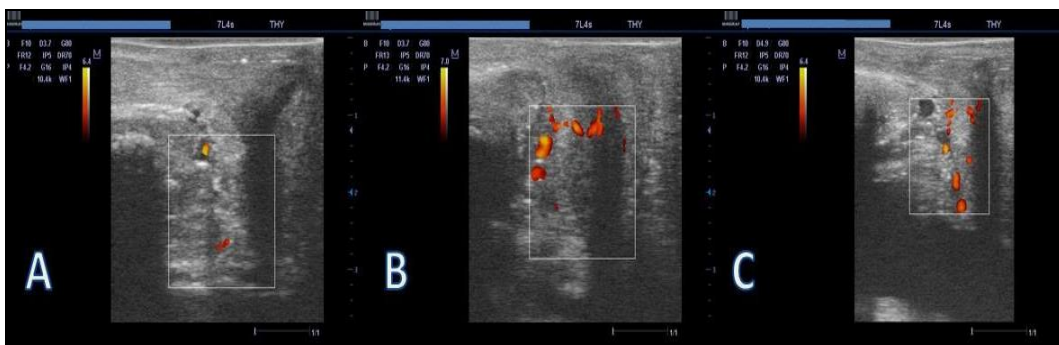


Fig 7: Angio-Doppler at pretreatment (A), post-treatment (B), and one month post-treatment (C).

At post-treatment, the group including one single LEDs session (group 2) had less edema and less inflammation, and at one month after procedure, arrived at similar levels of tissue neovascularization and epithelium regeneration, although in this group the values were higher but not statistically significant.

At post-treatment, differences between treatment groups were statistically significant for % increase of thickness AA ($P=0.0014$), % increase of thickness AP ($P=0.0003$), not significant for distance urethra-vagina, although the mean value was lower in group 2 ($P=0.0606$); and very significant for vascularization ($p<0.0001$). This might be explained by tissue of group 2 has less edema and inflammation than group 1 without LEDs session, after laser procedure. These differences can be observed in Figures 1, 2, 3 and 4.

In the follow-up visit, the tissue assessment revealed that both groups had similar results, with a slight trend to higher values in group 2, but without significant differences in the distance urethra vagina ($P=0.8565$), percentage of increase of distance AA ($P=0.8162$), percentage of increase of distance AP ($P=0.5837$) and increase of vascularization ($P=0.5578$). This additional tissue regeneration that seems to be generated by LEDs should be analyzed in further studies.

At one month post treatment, the anatomical results of both groups were similar, thus, the inclusion of LEDs therapy did not diminish the efficiency of any laser type.

Conclusions

This combined protocol including intra vaginal CO2 fractional vs Er: YAG fractional laser and intra vaginal LEDs emerge as a safe and effective procedure for VA treatment. Performing a phototherapy session with intra vaginal LEDs immediately after the laser procedure, appears to be effective in reducing post-treatment normal or expected transitory side effects, such as edema and inflammation and aiding in the regeneration of vaginal tissue, thus this may increase patient satisfaction. However, further studies with more samples and longer follow-up period, should be carried out.

Acknowledges

The authors want to thank all their collaborators and specially the i2e3 Biomedical Research Institute medical writer team.

References

1. Portman DJ, Gass MLS. Genitourinary syndrome of menopause new terminology for vulvovaginal atrophy from the International Society for the Study of Women's Sexual Health and the North American Menopause Society. *Menopause*. 2014; 21:1063-1068.
2. Nappi RE, Gardella B. Vulvo-vaginal atrophy. In *Managing the Menopause: 21st Century Solutions* (Mayo Foundation. 2015; 85:52-57.
3. Roy S, Caillouette JC, Roy T, Faden JS. Vaginal pH is similar to follicle-stimulating hormone for menopause diagnosis. *American Journal of Obstetrics and Gynecology*. 2004; 190:1272-1277.
4. Labrie F. Efficacy of intravaginal dehydroepiandrosterone (DHEA) on moderate to severe dyspareunia and vaginal dryness, symptoms of vulvovaginal atrophy, and of the genitourinary syndrome of menopause. *Menopause*. 2016; 23:243-256.
5. Abrahamse H. Regenerative Medicine, Stem Cells, and Low-Level Laser Therapy: Future Directives. *Photomedicine and Laser Surgery*. 2012; 30:681-682.
6. Arroyo C. Fractional CO2 laser treatment for vulvovaginal

atrophy symptoms and vaginal rejuvenation in perimenopausal women. *Int. J Womens. Health* 2017; 9:591-595.

7. Faubion SS, Sood R, Kapoor E. Genitourinary Syndrome of Menopause: Management Strategies for the Clinician. *Mayo Clinic Proceedings*. 2017; 92:1842-1849.
8. Patel Schallen K. Mechanisms of Action of the CO 2 RE Fractional CO 2 Laser on Vaginal and Vulvar Tissue and Effects on Female Genitourinary and Sexual Health, 2017.
9. Tadir Y. Light and energy based therapeutics for genitourinary syndrome of menopause: Consensus and controversies. *Lasers Surg. Med*. 2017; 49:137-159.
10. Chaves ME, de A, Araujo AR, de Piancastelli ACC, Pinotti M. Effects of low-power light therapy on wound healing: LASER x LED. *An. Bras. Dermatol*. 2014; 89:616-23.
11. Whelan HT. Effect of NASA Light-Emitting Diode Irradiation on Molecular Changes for Wound Healing in Diabetic Mice. *J Clin. Laser Med.* <html_ent glyph='@amp;' ascii='&' /> *Surg*. 2003; 21:67-74.
12. Kim WS, Calderhead RG. Is light-emitting diode phototherapy (LED-LLLT) really effective? *Laser Ther*. 2011; 20:205-15.
13. Karcher C, Sadick N. Vaginal rejuvenation using energy-based devices. *Int. J women's dermatology*. 2016; 2:85-88.
14. Gambacciani M, Levancini M, Cervigni M. Vaginal erbium laser: the second-generation thermotherapy for the genitourinary syndrome of menopause. *Climacteric*. 2015; 18:757-63.
15. Withagen M, Milani A, Vierhout M, Karram M. Surgery for cystocele I-questions. *Int. Urogynecol. J*, 2012; 23:661-662.
16. Bump RC. The standardization of terminology of female pelvic organ prolapse and pelvic floor dysfunction, 2012.